

## **CASE SPECIFIC PHOTOS CHECKLIST**

### **Standard Hand Photos**

Take *Initial Overalls*.

BEFORE UNDRESSING/CLEANING: Take a picture of the handbag on the hand.

Remove handbag and take pictures in the following order: Top of hand, lateral (thumb or pinky) side, other lateral (thumb or pinky) side, knuckles, fingertips, and then palm.

Repeat the above steps with other hand.

Be sure to get close ups of any injuries, GSR, or other findings you may see.

DO NOT clean the hands before taking hand photos.

Move on to the Basic Standard Exam Photo series starting with *Clean Overalls*.

Once the hands are cleaned, check again for any wounds that were missed when they were dirty and photograph.

### **Standard Gunshot Wound Photos**

Take *Initial Overalls*.

BEFORE UNDRESSING/CLEANING: Take a picture of the entrance wound, dirty. Get a perspective and then close-up. If there is an exit wound, do the same.

If there are handbags, take hand photos. (See above steps)

Take the Basic Standard Exam Photo Series starting with *Clean Overalls*.

Clean the entrance wound by using warm water and a towel. If soot is present, try to clean the area without removing the soot. You can also carefully shave the area to fully expose any stippling or muzzle imprints. Photograph the wound by getting a perspective shot and then close-up. If there is an exit wound, do the same.

It is recommended to use an 'L' ruler to show measurements of the defect(s). Remember that the ruler should be an ABFO approved ruler, the ruler should be touching the surface plane that is being captured, and the camera should be at a 90-degree angle to the defect being photographed.

### **Standard Hanging Photos**

Take *Initial Overalls*.

BEFORE UNDRESSING/CLEANING: Take photos of the ligature on the neck, if it is still there. Remove the ligature. If there is no ligature, proceed with the standard photo series.

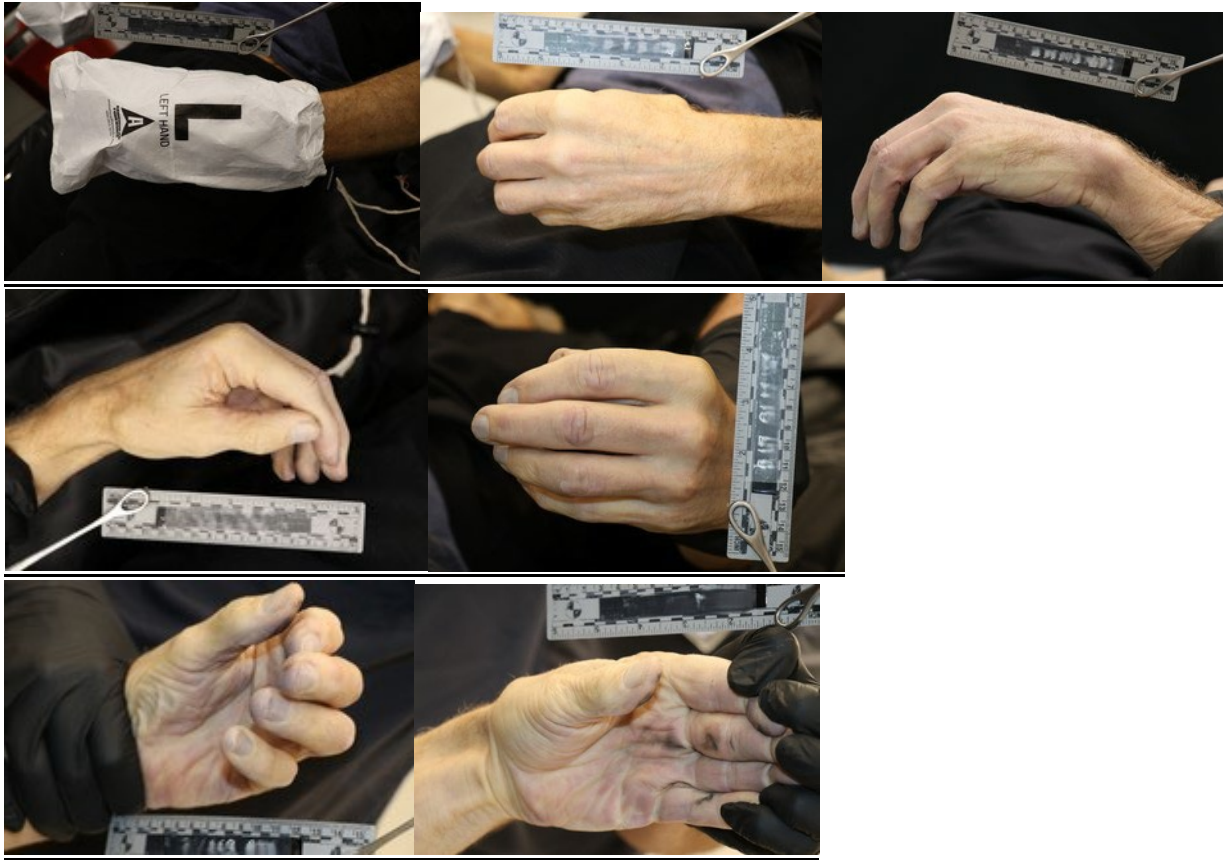
Take the Basic Standard Exam Photo Series starting with *Clean Overalls*.

Do "around the world" on the neck ensuring you capture all areas of the ligature furrow including the back of the neck. Depending on the body positioning, make sure to check behind the ears for furrowing.

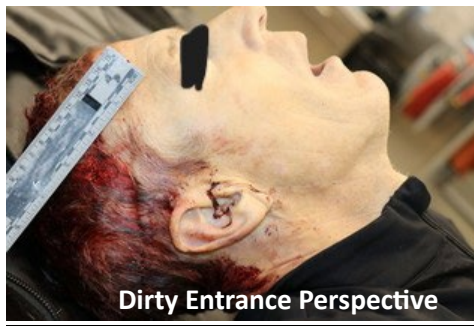It is recommended to also include eye photos to show presence or absence of petechiae. Do this by using forceps to grasp the inner eyelid and flip out. Do this for the top and bottom eyelid of each eye.

## EXAMPLES OF PHOTO SERIES

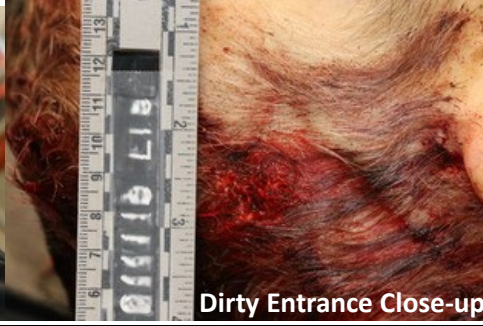### Standard Hand Photos:



**Standard Gunshot Photos:**



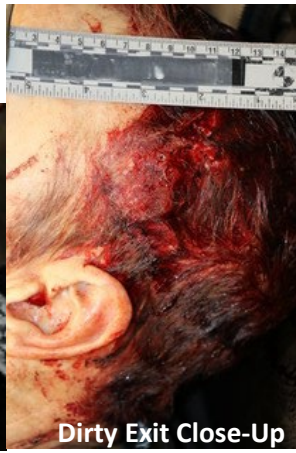**Dirty Entrance Perspective**



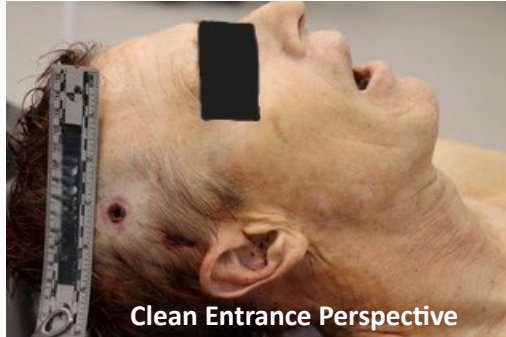**Dirty Entrance Close-up**



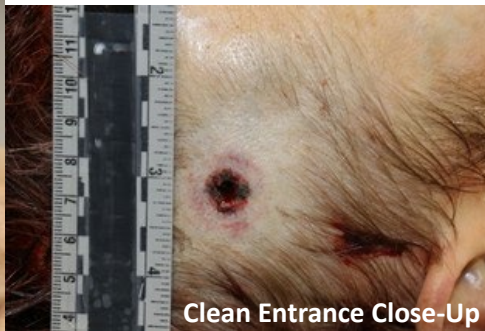**Dirty Exit Perspective**



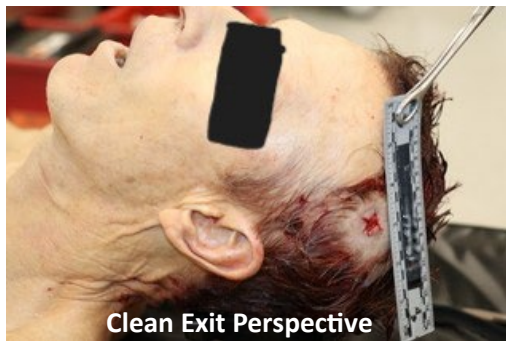**Dirty Exit Close-Up**



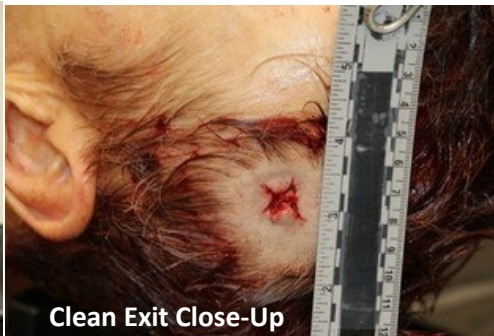**Clean Entrance Perspective**



**Clean Entrance Close-Up**



**Clean Exit Perspective**

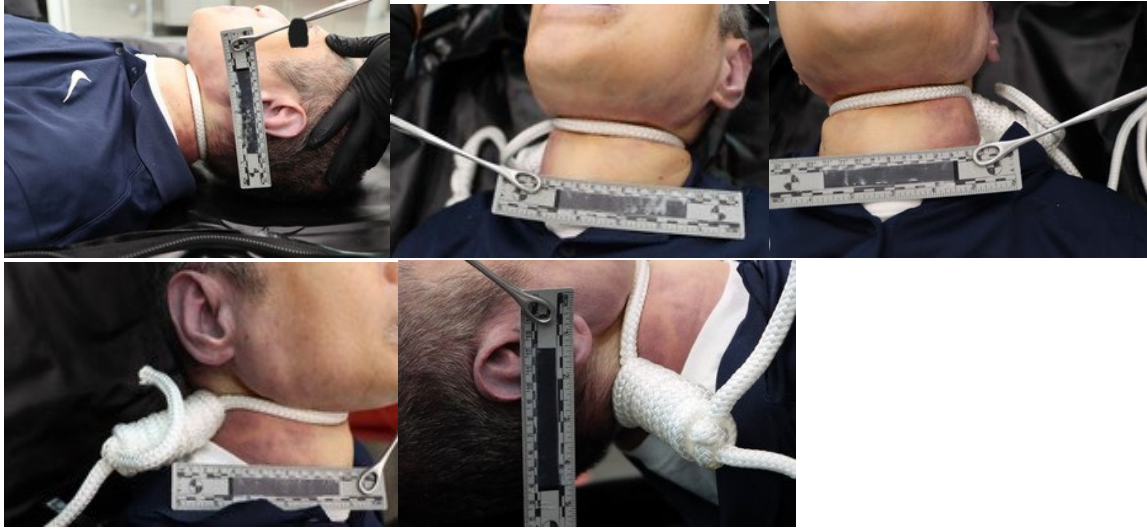

**Clean Exit Close-Up**

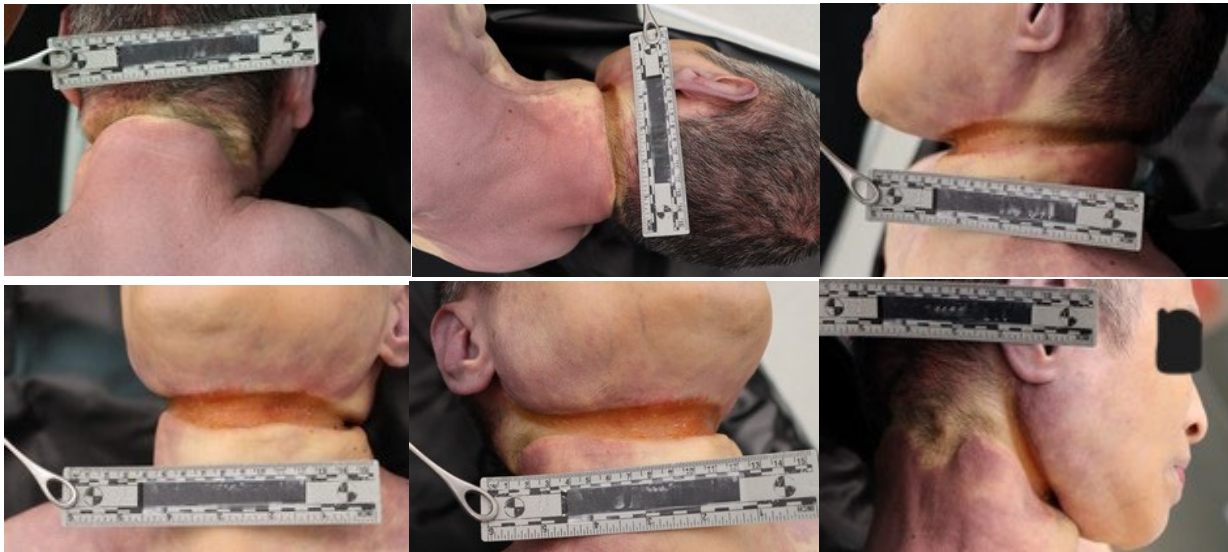


## **Standard Hanging Photos**

*If there is a ligature still on the decedent photo it on all the way around the neck. Include the knot:*



*Remove ligature. If no ligature, just start with furrow and go all the way around:*



*Eye photos:*

